

## INGUINAL LYMPH NODES AFTER COMBINED OZONE- AND PHYTOTHERAPY AT THE LATE STAGE OF ONTOGENESIS

<sup>2</sup>Gorchakova O.V., <sup>1</sup>Kutafeva N.V., <sup>1,2</sup>Gorchakov V.N.

<sup>1</sup>*Novosibirsk State University, Novosibirsk;*

<sup>2</sup>*Institute of Clinical and Experimental Lymphology, Novosibirsk, e-mail: vgorchak@yandex.ru*

---

We have done the analysis of the structural and functional zones of inguinal lymph nodes, taking into account age and phytotherapy in the experiment. We have obtained results which show a decrease in the functional activity of the lymphoid parenchyma on the background of the involution and sclerotic processes in the lymph node. We implemented the idea of enhancing nonspecific resistance by ozone and phytocorrection of the structure and function of the lymph node, which has undergone age-related changes. Positive effect was achieved through changing the size of the lymph node compartments, preservation of lymphoid nodules and strengthen neolymphogenesis at the late stage of ontogenesis. We review phytotherapy as a means of raising nonspecific resistance of the organism.

---

**Keywords:** lymph node, ozone- and phytotherapy, gerontology

The immune system has a leading role in the formation of nonspecific resistance of the organism. The structure of the immune system presents lymphoid tissue and in particular lymph nodes. Lymph nodes have any evolutionary and ontogenetically to ensure the immune status under the action of different environmental factors. Aging lymphoid tissue occurs with age and the inevitable decline of nonspecific resistance of the organism, especially in old age periods of life. A search of means and methods is a priority when you need to adjust the immune status and increase the body's resistance. The solution of one of actual problems of modern gerontology and lymphology is search of the means strengthening neolymphogenesis. This problem may be decided by overcoming affirmation of modern medicine that «new lymphoid organs are not formed at a late stage of ontogenesis» [4, 7, 8]. Ozone- and phytotherapy have the greatest interest among other treatment methods. They are used in endoecological rehabilitation on the basis of existing modern concepts of protective systems [7] and phytolymphonutritiology [4].

The purpose of the study was to evaluate the effect of combined ozone- and phytotherapy on the structure and function of the lymph node, which had undergone age-related changes.

### Materials and methods of research

The experiment was conducted with 160 white rats male Wistar with conventionally selected age groups: young animals at the age of 3–5 months (control group) and old animals aged 1,5–2 years (comparison group) taking into account the ratio of life expectancy of rats and humans. The animals had free access to water and were put on a standard diet. In elderly and senile age reduced function of the lymphatic system, which necessitates the use of lymphotropic technologies correction to increase nonspecific resistance of the organism. The choice is made in favor of ozone and phytotherapy, as they possess adaptogenic and lymphotropic effects of the action [4]. Orig-

nal herbal collection used in a daily dose of 0,1–0,2 g/kg during one month in these animals of different ages. A herbal combination including *Bergenia*, *Rhodiola rosea*, *Hedysarum*, *Rosa majalis*, *Thymus*, blueberry, cowberry, currant leaves and dietary fiber. The main active bioactive substances of plants are flavonoids, arbutin, dietary fiber, trace elements. Application of ozonized olive oil was carried out on the region of inguinal lymph nodes during 15–20 minutes every other day (total 14 procedures). Inguinal lymph nodes were investigated with histological method [3]. Histological sections of lymph nodes were stained with hematoxylin-eosin, azure-eosin and exposed to morphometric analysis [2] using the program Image-Pro Plus 4.1. The study used a statistical method with the arithmetical mean, the average squared error and the scientific validity of the data at  $p < 0,05$  using the program StatPlus Pro 2009, AnalystSoft Inc.

### Results of research and their discussion

It is shown that with age lymph nodes start suffering from functional load for involution in the presence of the morphological equivalents of compensation. The size of structural and functional zones changes and the lymph node structure becomes non-homogeneous (Table 1). At late stage of ontogeny is manifested by increase in 1,4 times of capsules ( $1,62 \pm 0,07\%$  compared with  $1,16 \pm 0,09\%$  in the control), in 1,6 times of the cortical plateau ( $1,90 \pm 0,08\%$  compared with  $1,20 \pm 0,09\%$  in the control), in 1,3 times of paracortex ( $8,94 \pm 0,49\%$  compared with  $7,14 \pm 0,67\%$  in the control), in 2,3 times of lymphatic sinus ( $2,94 \pm 0,20\%$  compared with  $1,30 \pm 0,12\%$  in the control) on the background of the decrease in 1,2 times of lymphoid nodules with germinal center ( $1,37 \pm 0,12\%$  compared with  $1,61 \pm 0,17\%$  in the control). The observed changes of the lymph node compartments are a reflection of the decrease of lymphoproliferation, sclerosis, involution of lymphoid tissue and antagonism of humoral and cellular elements of the immune system. All this leads to decreased immune function at a late stage

of ontogenesis. These changes are induced by an increasing disproportion between influx and efflux from lymph nodes. They mostly affect those lymph nodes, which did not underwent involution and conserved structural and functional zones constituting lymphoid nodule. It is therefore preservation of lymphoid nodule that defines the functions of lymph nodes significant at the late stage of ontogenesis and necessary for performing drainage and detoxification functions in the lymphatic region.

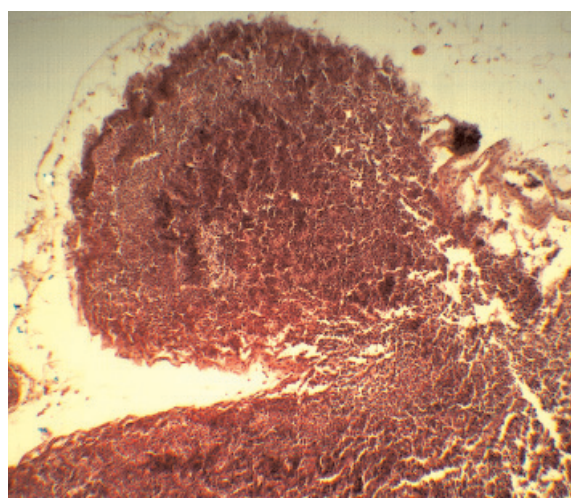
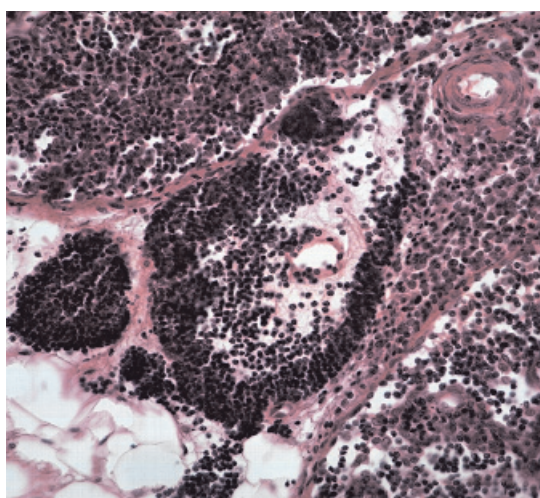
The combined ozone- and phytotherapy influences the structural organization of lymph nodes that underwent age-related changes (Table). There is a reduction in 1,3 times areas of the cortical plateau ( $1,45 \pm 0,19\%$  com-

pared with  $1,90 \pm 0,08\%$  without correction), paracortex ( $7,17 \pm 0,31\%$  compared with  $8,94 \pm 0,42\%$  without correction) and lymphatic sinus ( $1,61 \pm 0,11\%$  compared with  $2,94 \pm 0,20\%$  without correction). There is increased in 1,8 times the area of lymphoid nodules with germinal center ( $2,48 \pm 0,25\%$  compared with  $1,37 \pm 0,12\%$  without correction), in 1,2 times the area of medullary cords ( $6,04 \pm 0,48\%$  compared with  $5,02 \pm 0,34\%$  without correction). Ozone- and phytotherapy contributes to the preservation of lymphoid tissue and enhances immune potential of lymph nodes to the increase in proliferation and migration of lymphoid cells and optimize the size of sinus system at a late stage of ontogenesis.

The area of lymph node structures of young and old animals after ozone and phytotherapy, %

Structures of a lymph node	Young animals (3–5 months)		Old animals (1,5–2 years)	
	Control (without correction)	Ozone and phytotherapy	Control (without correction)	Ozone and phytotherapy
	1	2	3	4
Capsule	$1,16 \pm 0,09$	$1,07 \pm 0,08$	$1,62 \pm 0,07^*$	$1,74 \pm 0,11$
Subcapsular sinus	$0,57 \pm 0,07$	$0,59 \pm 0,05$	$0,41 \pm 0,04$	$0,58 \pm 0,05$
Cortex plateau	$1,20 \pm 0,09$	$1,57 \pm 0,16$	$1,90 \pm 0,08^*$	$1,45 \pm 0,19$
Lymphoid nodule with germinal center	$1,16 \pm 0,06$	$1,32 \pm 0,11^*$	$1,24 \pm 0,08$	$1,28 \pm 0,11$
Lymphoid nodule without germinal center	$1,61 \pm 0,17$	$1,85 \pm 0,21$	$1,37 \pm 0,12^*$	$2,48 \pm 0,25^\circ$
Paracortex	$7,14 \pm 0,67$	$5,84 \pm 0,44$	$8,94 \pm 0,49$	$7,17 \pm 0,62$
Medullary cords	$5,20 \pm 0,32$	$5,02 \pm 0,38$	$5,02 \pm 0,34$	$6,04 \pm 0,48$
Medullary sinus	$1,30 \pm 0,12$	$0,94 \pm 0,08$	$2,94 \pm 0,20^*$	$1,61 \pm 0,11^\circ$

Note.  $*P_{1-2,3} < 0,05$ ,  $^\circ P_{3-4} < 0,05$  – the differences were significant.



Lymphoid infiltration with separate lymphoid nodule (left) and fragmentation of parts of the lymph node (right) after ozone and phytotherapy at a late stage of ontogeny. Stained with hematoxilin and eosin. The magnification of ocular 7x by objective 4x

There is information about neolymphogenesis in the literature [1, 5, 6, 8]. We have established the effect of neolymphogenesis after ozone and phytotherapy. We revealed the ectopic formation of lymphoid follicles in the subcapsular zone and in the medullary substance of lymph node. Evidence of the formation of lymphoid follicles is the absence of CD38+cells [7]. Ozone and phytotherapy enhances lymphoproliferation and leads to the accumulation of lymphocytes and the formation of lymphoid nodules (follicles) outside the lymph node (Figure). Regeneration of lymphoid tissue outside the lymph node is a sign of compensation for age-induced changes. There is hyperplasia of the individual structural and functional areas, and the fragmentation of lymph node due to the separation of parts of the cortex (Figure). Small lymphoid nodules often found in the tissue around inguinal lymph nodes. The formation of new lymphoid structures located outside of the lymph node is the result of changes of lymphatic drainage after ozone and phytotherapy. Ectopic accumulations of lymphoid cells are called «tertiary lymphoid organs» and they are described usually in pathological situations associated with varying degrees of immunodeficiency [1, 6, 8]. We consider neolymphogenesis as manifestation of regeneration, resulting in increased immunodeficiency at the late stage of ontogenesis after phytotherapy.

Thus, at the late stage of ontogenesis, the structure of lymph nodes is reorganized, which reflects the general process of ageing. The combined ozone- and phytotherapy has a modulating effect on structural and functional zones accompanied by an increasing proliferation of lymphoid cells and intense neolymphogenesis. The result is of practical importance to enhance the nonspecific resistance of the organism and efficiency of the endoecological rehabilitation in elderly and senile age.

#### References

1. Aloisi F., Pujol-Borrell R. Lymphoid neogenesis in chronic inflammatory diseases // *Nat. Rev. Immunol.* – 2006. – Vol. 6. – P. 205–217.
2. Avtandilov G.G. Medical morphometry. – M.: Meditsina, 1990. – 384 p.
3. Belyanin V.L., Tsyplakov D.E. Diagnosis of lymph node reactive hyperplasia. – SPb.-Kazan: Tipografija izdatelstva “Chuvashija” – 1999. – 328 p.
4. Gorchakov V.N., Saranchina E.B., Anokhina E.D. Phytolymphonutriciology // *Practical phytotherapy.* – 2002. – № 2. – P. 6-9.
5. Gorchakova O.V., Gorchakov V.N. Lymphoadenogenesis as life-support process through prism of natural evolution and expediency at senile age // *Internationaler medizinischer Kongress & Fachmesse «Euromedica-2014»: Moderne Aspekte der Prophylaxe, Behandlung und Rehabilitation.* 5–6. Juni 2014. – Hannover, 2014. – P. 70–71.
6. Greter M., Hofmann J., Becher B. Neo-lymphoid aggregates in the adult liver can initiate potent cell-mediated immunity // *PLOS Biol.* – 2009. – Vol. 5. – № 7(5). – DOI: 10.1371/journal.pbio.1000109.
7. Kononov V.I., Borodin Yu.I., Lyubarskiy M.S. Lymphology. – Novosibirsk, 2012. – 1014 p.
8. Mebius R.E. Organogenesis of lymphoid tissues // *Nat. Rev. Immunol.* – 2003. – Vol. 3(4). – P.292–303.